


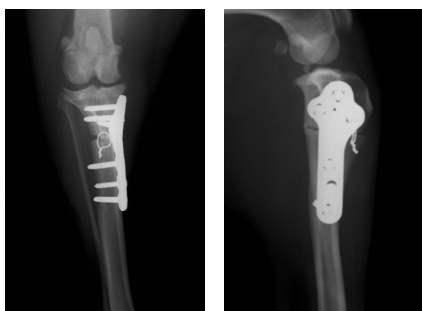
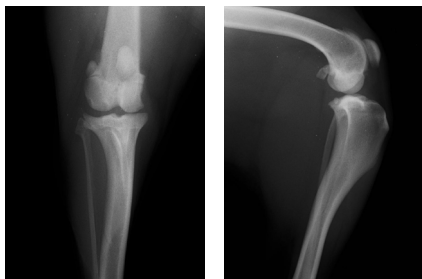
Focus on: Cruciate Disease

Did you know that cruciate disease is the most common orthopaedic condition affecting our canine friends? Well, we wanted to share with you the story of one brave patient and his family, who last year went through the journey of a ruptured cruciate ligament.



Meet Bruce!

Bruce, the very handsome 9 year 8-month-old English Springer Spaniel, presented to his primary care practice in Spring 2023 having become acutely lame on his left pelvic limb. On examination, pain was elicited to his stifle so initial thoughts turned to potential cruciate disease however, as Bruce was otherwise well, his vet recommended a period of conservative management including restricted exercise and the introduction of a non-steroidal anti-inflammatory drug. Unfortunately, Bruce remained lame, so x-rays were the next step.



Examination findings:

- Lameness
- Discomfort on palpation of the stifle
- Joint swelling
- Muscle atrophy
- Positive cranial drawer
- Positive tibial thrust
- Stifle effusion
- Medial buttress

A free x-ray report was turned around within 24 hours and Bruce was booked in for a plateau levelling procedure; specifically a Cranial Closing Wedge Osteotomy (CCWO), the preferred technique of attending surgeon, Nicci.

Surgery considerations:

- Has your client received a ProVetSurg [pre-op info sheet](#)?
- Is there a preferred day for booking an orthopaedic procedure? Consider practice/client convenience.
- Has your client got a good recovery set-up ready? A confined space such as a crate or utility room with non-slip mats is perfect for a recovering patient.
- Do you have a ProVetSurg [surgical checklist](#)?
- Are the appropriate medications available? Methadone, IV Paracetamol, Cefuroxime, Bupivacaine.
- Do you require a ProVetSurg RVN to join the surgeon? Available upon request.

On Bruce's surgery day, Nicci met with his family, discussed the procedure and answered all their questions before admitting him. A medial mini arthrotomy revealed complete rupture of the cranial cruciate ligament, while confirming that the menisci were intact. CCWO was performed with a 20-degree osteotomy, reduced with orthopaedic wire and stabilised with a 3.5mm N2 TPLO plate in compression. Post op x-rays revealed that implants were well placed so Bruce was recovered from his

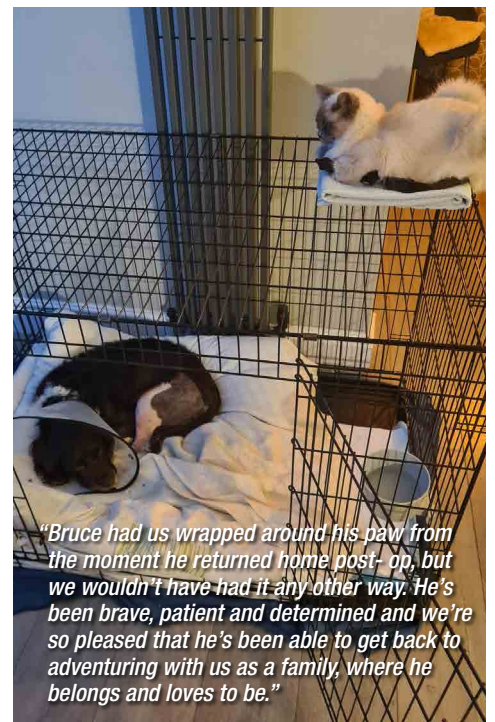anaesthetic ready to begin his rehab programme.

On Bruce's return home, he was blessed with the care of his exceptionally doting family who made sure that he had all the home comforts he could possibly wish for – a king-size duvet and electric log burner were just a few mentioned! One particular family member that couldn't see Bruce on his own was Margot, his feline – sister, pictured here looking over her 'big-brother's' temporary castle.

Short lead walks and controlled physio exercises were the key to Bruce's journey before 'X-ray day' then came – offering great news as Nicci could confirm that Bruce's osteotomy was healing nicely.

Clinical exam also showed improved joint comfort, no lameness and an all-round happier Bruce, and family! Further rehab commenced after this time, giving Bruce the opportunity to put his 'sea-legs' on and take to the under-water-treadmill, hydrotherapy pool and wobble boards at Beacroft Referrals.

Recent communication with Bruce's family has been positive.

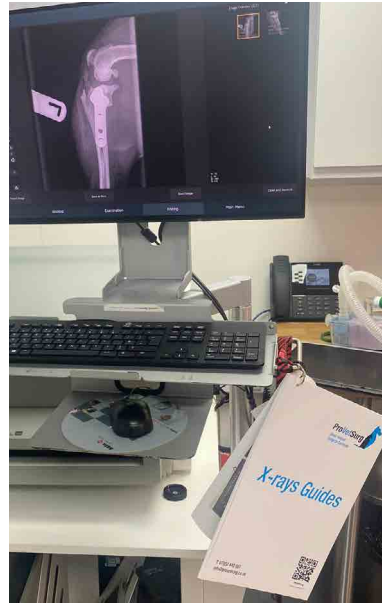


"Bruce had us wrapped around his paw from the moment he returned home post-op, but we wouldn't have had it any other way. He's been brave, patient and determined and we're so pleased that he's been able to get back to adventuring with us as a family, where he belongs and loves to be."

In line with Bruce's story, we are very pleased to support the [RCVS Canine Cruciate Registry](#) a professional platform, dedicated to monitoring the outcomes of canine cruciate disease. Here, our orthopaedic surgeons have peace of mind that their chosen technique, whether that be a TPLO, CCWO or Lateral Suture, is being regularly analysed to ensure it is the very best they could offer for the patients they meet.



Have you seen our new X-ray Guides?



Towards the end of 2023, we introduced a user-friendly and compact selection of radiograph guidelines that you can reach for when taking those all-important views in the X-ray room. Hang them up, stick to them to your walls or keep them safely in 'that drawer' in prep where all the good stuff lives! From stifles to hips, elbows to carpi, we hope that we've covered the most asked for positions. Now grab your ProVetSurg X-ray marker, get the sandbags and foam wedges at the ready and feel confident that you can ace that medio-lateral stifle or ventro-dorsal extended pelvis! Not forgetting a wadge of cotton wool and your trusty roll of Elastoplast as they're pretty handy too! Find a copy on our website.

Always aiming high

We pride ourselves on maintaining high standards across our patient and client care, but you might ask, how do we do this?

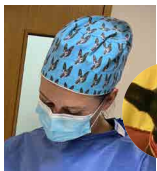- Clinical Audit
- Clinical Club
- M & M rounds
- Inhouse CPD

As a team of peripatetic surgeons and nurses delivering an abundance of surgical and non-surgical procedures in a variety of settings, we recognise the importance of reviewing and reflecting in order to learn how we can constantly improve our services. The above team-led platforms enable us to do just this in a supportive, encouraging and safe space so that we can be sure we're always learning, progressing and delivering our patients the very best in veterinary care.

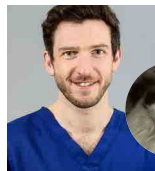Meet our team



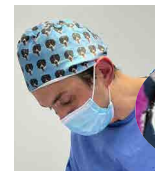This scoop we wanted to share with you 'the faces behind our hats'! As you might have seen, we've been sporting our Pet Face Scrub Hats for a little while now, from the brilliant company **'All Scrubbed Up'** - these are indeed featuring our very own furry-friends – so we thought it's about time we introduced them to you!



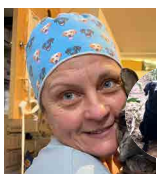Dr Nicci Meadows
Surgeon
BVetMed CertAVP GSAS
MRCVS
'Fly' the long-snouted X-breed



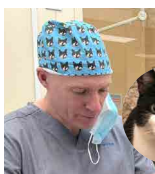Dr Rob Quinn
Surgeon & Clinical Advisor
BVMS(Hons) CertAVP
DipECVS MRCVS Recognised
& EBVS European Specialist
in Small Animal Surgery
'Millie' the Ragdoll



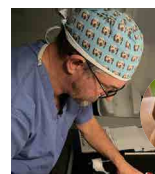Dr Ivan Filipovic
Surgeon
DVM, PgC (SAS)
'Flocki' the Border Collie



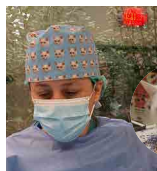Dr Heidi Burkinshaw
Surgeon
BSc(Hons) BVetMed
PgC(SAS) MRCVS
'Fizz' & 'Indie' the Labradors



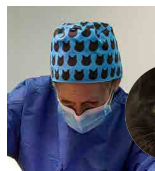Dr Dan Troup
Surgeon
BSc (Hons) BVSc MRCVS
'Basil' the Domestic Short Hair



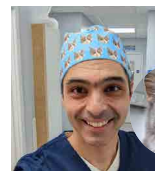Dr Edric Cross
Surgeon
BVetMed CertSAS MRCVS
RVCS
'Crumble' the Hungarian Vizsla



Dr Ana Murta
Surgeon
MSc, PgC SAS, MRCVS
'Pipas' the Domestic Short Hair



Dr Sam Marshall
Surgeon
MA VetMB CertSAS MRCVS
RCVS Recognised Advanced
Practitioner in Small Animal
Surgery
'Harry' the Domestic Long Hair



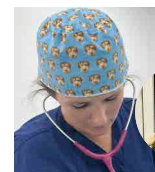Dr Chris Nikolaou
Surgeon
DVM CertAVP GSAS MRCVS
'Mister' the Domestic Long Hair



Dr Ana Afonso
Surgeon
DVM GPCert(DI) PgC(DI)
MRCVS
'Seruga' the Domestic Short Hair



Bev Morgan
Surgical Nurse &
Case Coordinator
RVN
'Foxy' the Cocker Spaniel



Lauren Haighton
Surgical Nurse &
Case Coordinator
RVN CertVNECC
'Curly' the Welsh Terrier

We are on Instagram, LinkedIn and Facebook – catch the latest news on our social pages

